

# Medical Thermography

## CASE STUDIES

Dr. William Amalu, President

International Academy of Clinical Thermography

### ***Clinical Earthing Application in 20 Case Studies.***

Researcher: William Amalu, DC, DABCT, FIACT

The case studies presented were performed out of an out-patient clinical treatment center in Redwood City, California. The subjects were randomly selected out of the treatment database as they presented for care. Each subject consented to inclusion in the study. Pain levels were assessed and followed using the standardized four point visual analogue pain scale. Thermal imaging of each subject was undertaken utilizing standardized pre-examination preparation protocols and strict image acquisition according to published guidelines. Some of the subjects were supplied with an *earthing* sleep system consisting of bedding containing conductive fibers, which was placed on top of the subject's mattress and thereafter connected to the earth via a conductive ground cord and an *earthed* ground rod. Other subjects were given clinical *earthing* treatments, which entailed the use of conductive electrode adhesive patches that were attached to the skin at specific points and thereafter coupled to the earth via a conductive ground wire that was connected to an earthed ground rod. All of the subjects were followed over time and their results recorded and summarized.

Use of high-resolution medical infrared imaging as an objective assessment of both inflammatory and neurophysiologic conditions demonstrated significant immediate changes in both acute and chronic inflammation related conditions.

ETT is showing incredible promise as one of the most significant advances in the treatment of both acute and chronic inflammatory conditions.

Note: Throughout this document, the term *Electron Transfer Technology* (ETT), is used as another term for "*earthing*" – coupling the human body with the earth.

## Case Study #1 – 49-year-old female

**The thermographic images below show the dramatic improvement in circulation and significant response to decreased pain after only 4 nights sleeping on the Electron Transfer Technology sleep system**

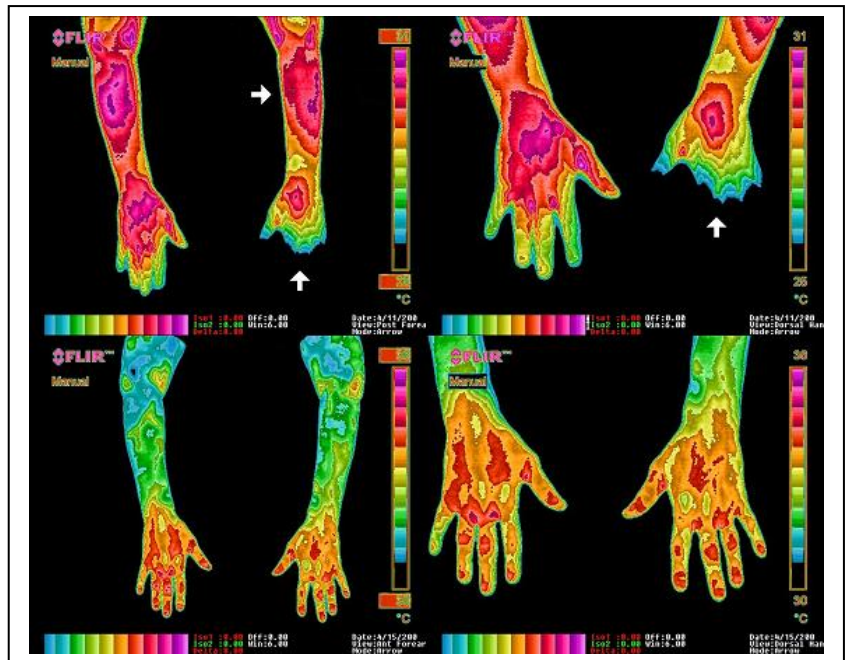
The case presented below was taken from a randomized clinical controlled study. Each subject was provided with an Electron Transfer Technology sleep system (ETT) on 4-11-05 and observed for changes with clinical visits every 48 hours for 5 days. Progress was monitored with High-Resolution Medical Infrared Imaging and standardized clinical outcome assessment questionnaires (quadruple visual analogue pain scales and sleep).

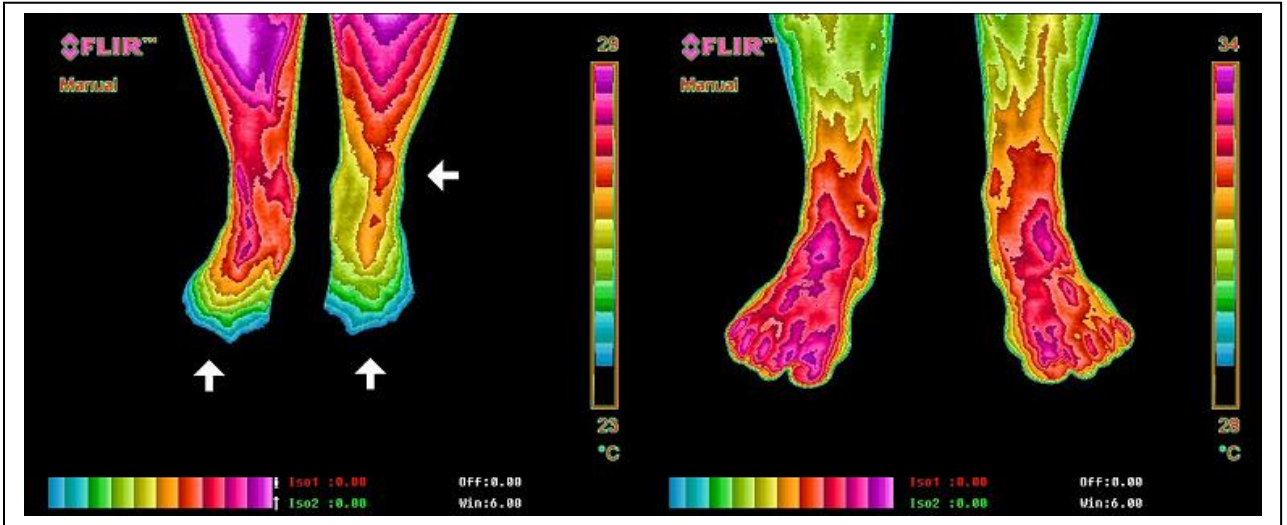
The patient in this study presented on 4-11-05 as a 49-year-old female with the following complaints: chronic neck and upper back pain, pain interfering with sleep, lack of sleep interfering with daily functioning, leg achiness/restless legs during sleep, and waking stiff and sore. The patient had previously tried medical and alternative treatments with poor results.

On 4-15-05, after 4 nights of sleeping on the ETT system, the patient reported a 67.5% reduction in pain, a 42.9% reduction in a lack of sleep interfering with daily functioning, a 28.6% reduction in pain interfering with sleep, a 75% reduction in leg achiness/restless legs during sleep, and an 80% reduction in waking stiff and sore. Steady continued improvement was reported by the patient on a 5-31-05 follow-up.

Her infrared images show a significant change with a pronounced improvement in circulation in the left upper extremity and both lower extremities. The images below show the significant changes from the baseline images taken on 4-11-05 (before ETT use) to the final images taken on 4-15-05 after 4 nights of sleeping on the ETT system.

The top row images are of the upper extremities taken as a baseline on 4-11-05 (prior to ETT use). The arrows denote the areas of poor circulation. The temperature of the left hand is so low that the fingers are at the same temperature as the room and cannot be seen (thermal amputation). The bottom row images were taken on 4-15-05 after 4 nights of sleeping on the ETT system. Note the significant improvement in circulation with a return of normal thermal symmetry in both upper extremities.





The above image on the left is of the lower extremities taken as a baseline on 4-11-05 (prior to ETT use). The arrows denote the areas of poor circulation. The temperature of both feet are so low, especially the left, that the toes are at the same temperature as the room and cannot be seen (thermal amputation). The image on the right was taken on 4-15-05, after 4 nights of sleeping on the ETT system. Note the significant improvement in circulation with a return of normal thermal symmetry in both feet.

## Case Study #2 – 65-year-old female

**The thermographic images below show the dramatic reduction in inflammation that resulted in near complete alleviation from pain after only 4 nights sleeping on the Electron Transfer Technology sleep system**

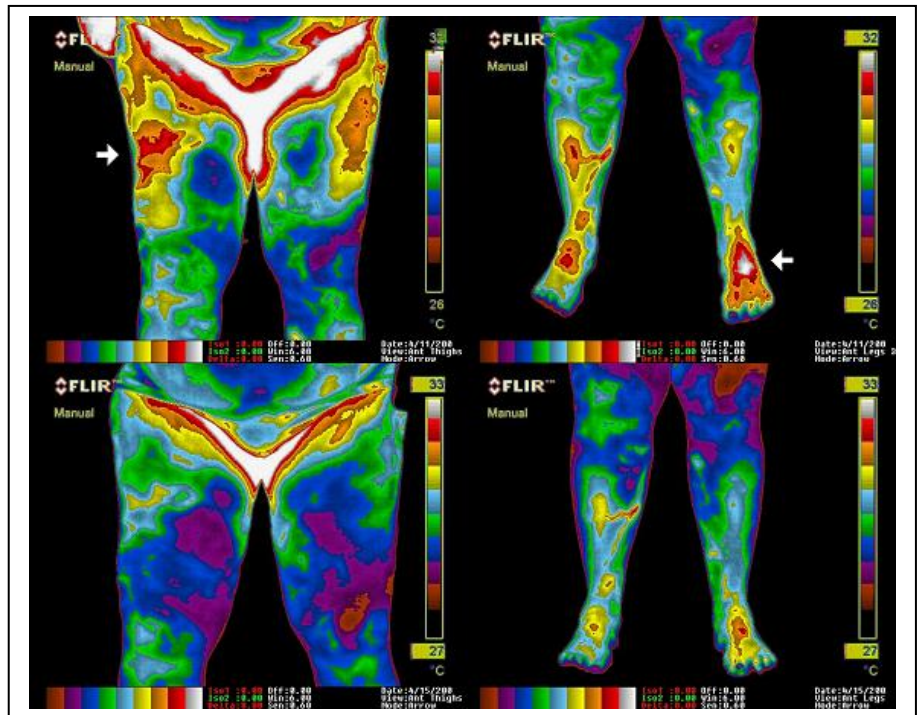
The case presented below was taken from a randomized clinical controlled study. Each subject was provided with an Electron Transfer Technology sleep system (ETT) on 4-11-05 and observed for changes with clinical visits every 48 hours for 5 days. Progress was monitored with High-Resolution Medical Infrared Imaging and standardized clinical outcome assessment questionnaires (quadruple visual analogue pain scales and sleep).

The patient in this study presented on 4-11-05 as a 65-year-old female with the following complaints: chronic bilateral thigh pain increased on the right to include the hip area, right knee pain and catching, bilateral ankle and foot pain with swelling increased on the left, insomnia, non-restful sleep, lack of sleep interfering with daily functioning, sleepiness during the day, pain interfering with sleep, leg achiness during sleep, and waking stiff and sore. The patient has been on prolonged medical treatment with poor results.

On 4-15-05, after 4 nights of sleeping on the ETT system, the patient reported a 91.6% reduction in pain, 50% improvement in restful sleep, 50% reduction in insomnia, a 50% reduction in a lack of sleep interfering with daily functioning, 50% reduction in sleepiness during the day, an 81% reduction in pain interfering with sleep, 50% reduction in leg achiness during sleep, and a 50% reduction in waking stiff and sore. The patient reports steady continued improvement as of a 5-31-05 follow-up.

Her infrared images show a significant change with a pronounced improvement in inflammation in the right upper thigh/hip region and both ankles/feet especially on the left. The images below show the significant changes from the baseline images taken on 4-11-05 (before ETT use) to the final images taken on 4-15-05 after 4 nights of sleeping on the ETT system.

The top row images are of the lower extremities taken as a baseline on 4-11-05 (prior to ETT use). The arrows denote the most significant areas of inflammation, which correspond precisely with the subject's areas of complaint. The bottom row images were taken on 4-15-05 after 4 nights of sleeping on the ETT system. Note the significant reduction in inflammation and a return towards normal thermal symmetry.





### **Case Study #3 – 85-year-old male**

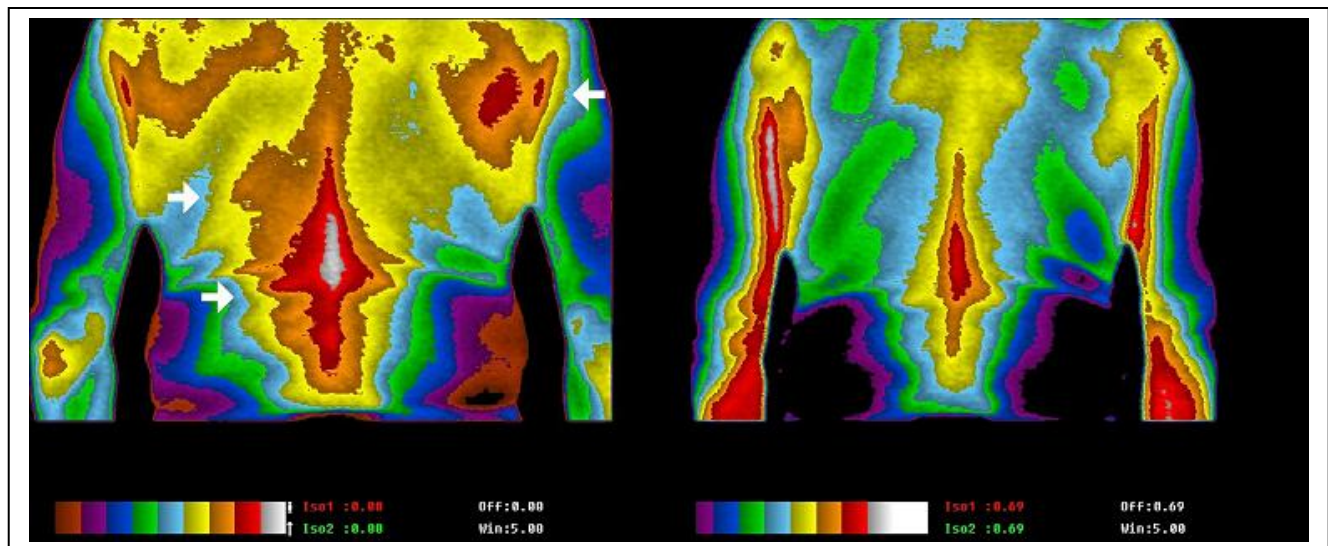
***The thermographic images below show the dramatic reduction in inflammation that resulted in significant pain resolution after only 2 nights sleeping on the Electron Transfer Technology sleep system***

The case presented below was taken from a randomized clinical controlled study. The subject was provided with an Electron Transfer Technology sleep system (ETT) on 8-9-04 and observed for changes with occasional follow up clinical visits over an 8 week period. Progress was monitored with High-Resolution Medical Infrared Imaging and standardized clinical outcome assessment questionnaires (quadruple visual analogue pain scales and sleep).

The patient in this study presented on 8-9-04 as a 85-year-old male with significant chronic left low back pain, chronic recurring right shoulder pain, pain interfering with sleep, and waking stiff and sore over a 4 month period. The patient had been on prolonged medical treatment with poor results.

On 8-11-04, after 2 nights of sleeping on the ETT system, the patient reported a 50% reduction in pain, an 80% reduction in pain interfering with sleep, and a 75% reduction in waking stiff and sore. After using the ETT sleep system for 4 weeks, the patient reported total resolution of his back and shoulder pain with only occasional mild stiffness. At this time the patient commented that “I have my life back”.

His infrared images show a significant change with a pronounced improvement in inflammation in the left lower back and right shoulder region. The images below demonstrate the significant changes from the baseline images taken on 8-9-04 (before ETT use) to the final images taken on 8-11-04 after 2 nights of sleeping on the ETT sleep system.



The image on the left is of the low back and shoulders taken as a baseline on 8-9-04 (prior to ETT use). The arrows denote the most significant areas of inflammation, which also correspond precisely with the subject’s areas of complaint. The image on the right was taken on 8-11-04 after 2 nights of sleeping on the ETT sleep system. Note the complete resolution in inflammation with a return of normal thermal symmetry.

## Case Study #4 – 48-year-old female

### ***The thermographic images below show a dramatic reduction in 6 years of chronic inflammation after only 30 minutes exposure to Electron Transfer Technology***

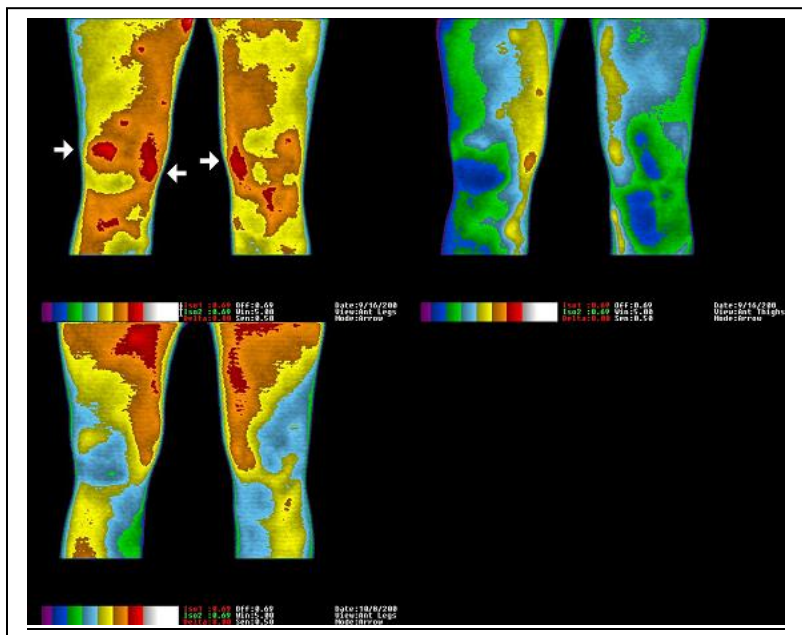
The case presented below was taken from a randomized clinical controlled study. The subject was exposed to clinical Electron Transfer Technology (ETT) on 9-16-04 and observed for changes 30 minutes later and followed up with clinical visits over a 12 week period. Progress was monitored with High-Resolution Medical Infrared Imaging and standardized clinical outcome assessment questionnaires (quadruple visual analogue pain scales).

The patient in this study presented on 9-16-04 as a totally disabled 48-year-old female with significant chronic bilateral knee pain (increased on the right), swollen knees, and fatigue over the past 6 years. The subject's condition began as a result of an injury sustained while using a ladder. The patient had received 3 knee surgeries, prolonged medical treatment, and physical therapy with poor results. The patient presented with knee wrap supports, a pronounced limp, and the need for a walker in order to ambulate.

On 9-16-04, after 30 minutes of exposure to clinical ETT, the patient reported a 20% reduction in pain that lasted for 24 hours. After 5 days of clinical ETT, the patient reported a 30% reduction in pain with an increase in energy that she described as "almost back to my normal self." After 2 weeks of treatment the patient felt good enough to try dancing and reported no increase in symptoms afterward. By 3 weeks the patient no longer needed her walker. After 6 weeks of treatment the patient's limp resolved. At week 12 the subject reported an overall 90% reduction in pain and swelling and noted that "I can't believe I have my life back."

Her infrared images show a significant change with a pronounced improvement in inflammation in both knees. The images agree with the patient's statement that her symptoms are worse on the right.

The top row of images is of the knees taken before and after 30 minutes exposure to clinical Earthing on 9-16-04. The arrows denote the most significant areas of inflammation. Note the considerable reduction in inflammation in the right image taken after 30 minutes of exposure to clinical ETT. The image on the bottom left was taken on 10-8-04 before treatment. The image shows a return of normal thermal symmetry with significant reduction in inflammation.



## Case Study #5 – 33-year-old female

### ***The thermographic images below show a dramatic reduction in 18 years of chronic inflammation after only 30 minutes exposure to Electron Transfer Technology***

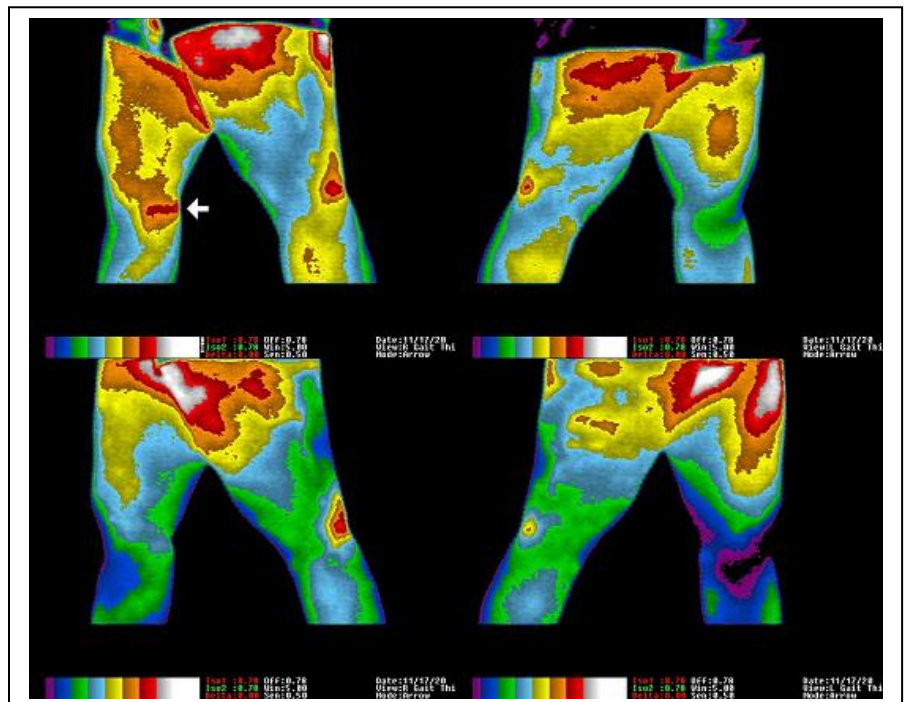
The case presented below was taken from a randomized clinical controlled study. The subject was exposed to clinical Electron Transfer Technology (ETT) on 11-17-04 and observed for changes 30 minutes later and followed up with clinical treatment over a 12 week period. Progress was monitored with High-Resolution Medical Infrared Imaging and standardized clinical outcome assessment questionnaires (quadruple VAS).

The patient in this study presented on 11-17-04 as a 33-year-old female with significant chronic right medial knee pain with swelling and instability over the past 18 years. The subject's condition began as a result of a gymnastics injury at the age of 15. The patient reported that she was unable to stand for long periods and that simple actions such as driving increased the symptoms. She also noted that she needed to sleep with a pillow between her knees to decrease the pain. The patient had been undergoing medical treatment and physical therapy on and off for many years with minimal results. The patient presented with considerable right medial knee tenderness and a mild limp.

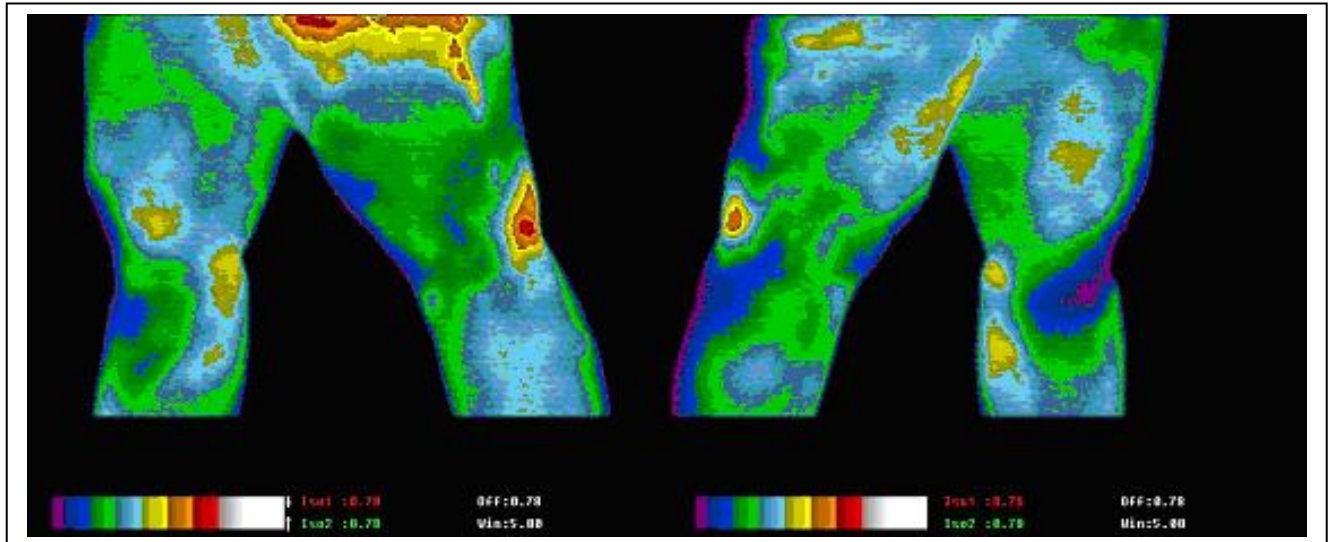
On 11-17-04, after 30 minutes of exposure to clinical ETT, the patient reported a mild reduction in pain. After 6 days of clinical ETT, the patient noted a 50% reduction in pain. She also advised that she could stand for longer periods without pain and that she no longer needed a pillow between her legs when she slept. After 4 weeks of treatment the patient felt good enough to play soccer, and for the first time in 15 years she felt no instability and little pain. By 12 weeks, the subject reported an 87% reduction in pain, no swelling, and for the first time in 15 years she went waterskiing. The patient contacted the office on 5-23-05 to report that she had finished a half-marathon, something she never dreamt she would ever be able to do.

Her infrared images show a significant change with a pronounced improvement in inflammation in the right knee. The images correlate precisely with the area of chronic pain.

11-17-04: The top row of images is of the knees taken in the walking position exposing the inside of both knees. The arrow points to the exact location of the patient's pain and denotes a significant area of inflammation. Note the considerable reduction in inflammation in the bottom row of image taken after 30 minutes of exposure to clinical ETT.







The above image was taken before treatment on 11-24-04. The image shows a near normal return of thermal symmetry with a significant reduction in inflammation in the right medial knee area.



The photo on the left is of the patient as she crosses the finish line. After 18 years of chronic knee pain, she has recovered to race and finish a half-marathon.



## **Case Study #6 – 84-year-old female**

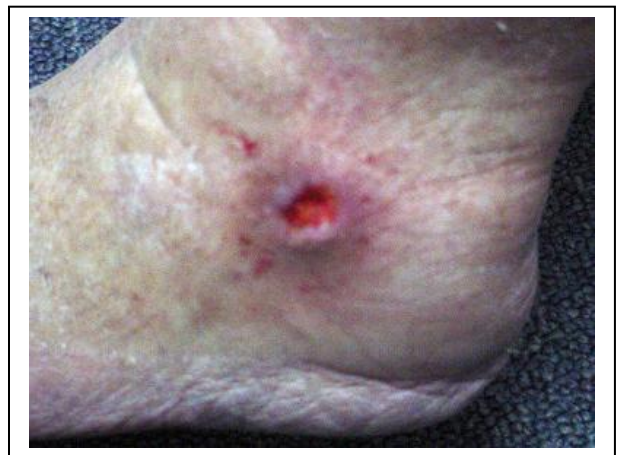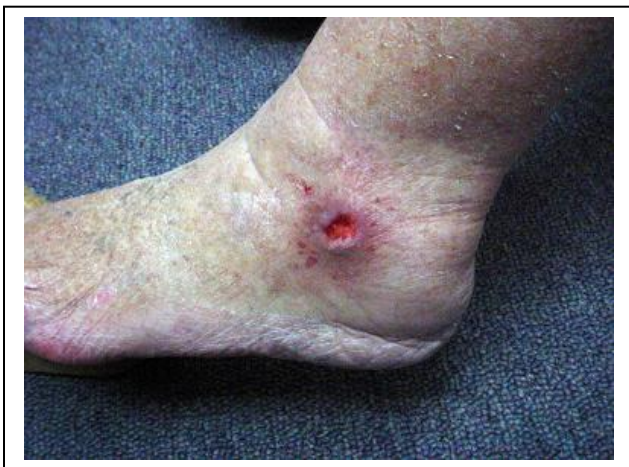### ***The forensic photos below show dramatic accelerated healing of an 8 month old open wound after only 2 weeks exposure to Electron Transfer Technology***

The case presented below was taken from a randomized clinical controlled study. The subject was initially exposed to clinical Electron Transfer Technology (ETT) on 10-29-04 and followed up with daily 30 minute clinical ETT treatments over a 2 week period. Progress was monitored with forensic photography and standardized clinical outcome assessment questionnaires (quadruple visual analogue pain scales).

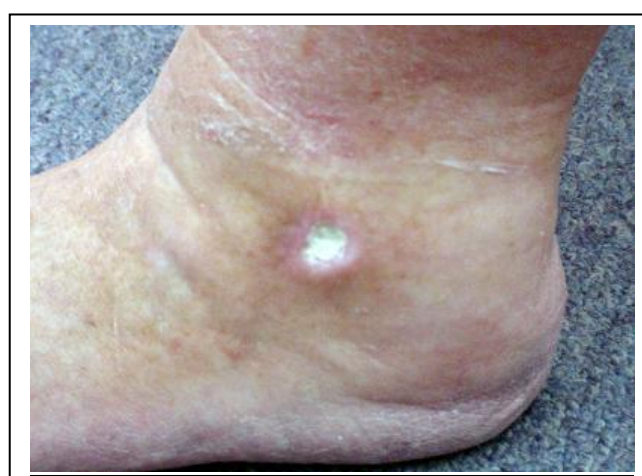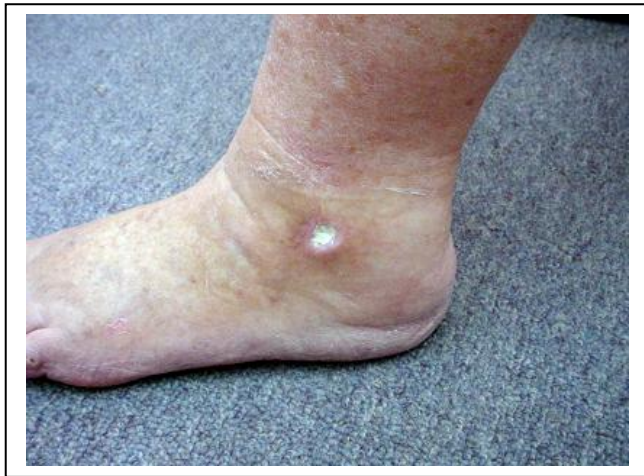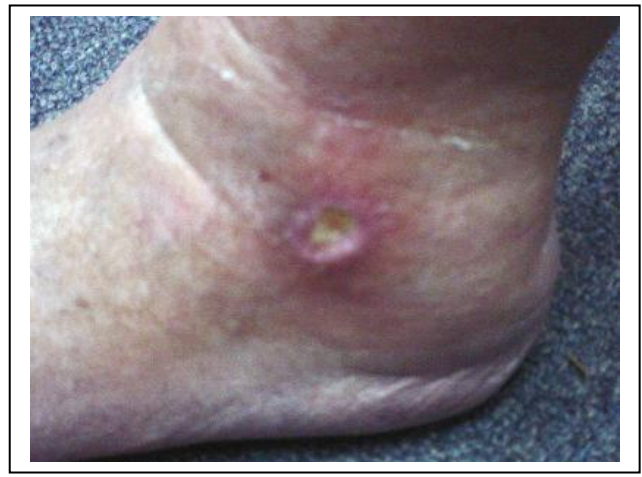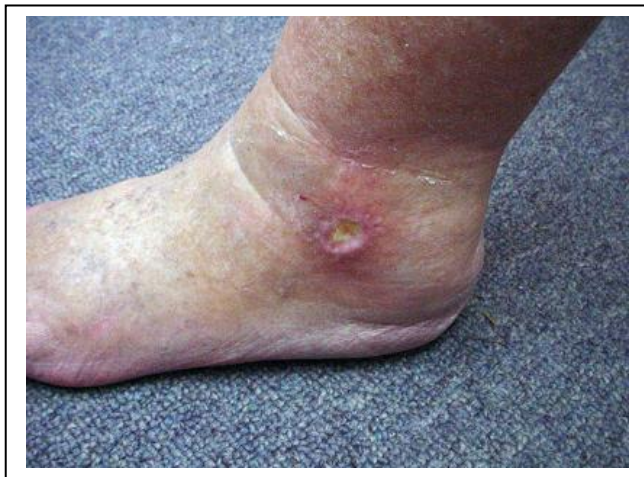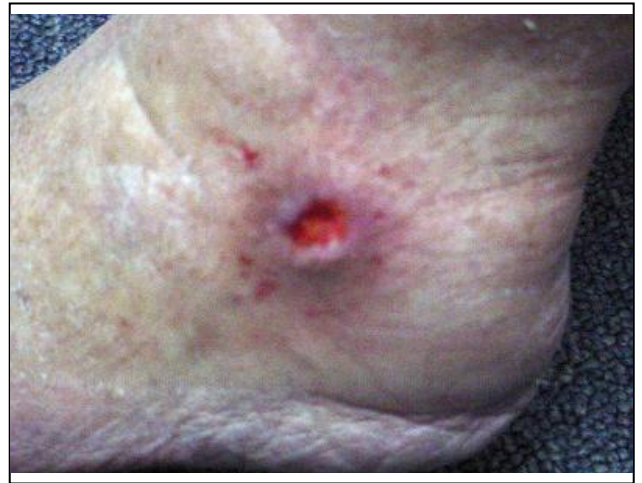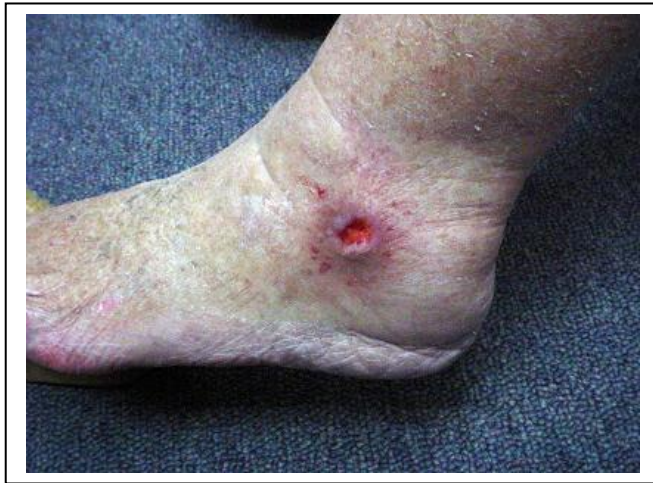The patient in this study presented on 10-29-04 as an 84-year-old female with an 8 month old unhealed open wound on the left ankle with pain in the same region. The subject's condition began as a result of a poorly fitted boot. A few hours after wearing the boot, a blister formed on the lateral aspect of the left ankle in the region of the inferior lateral malleolus. The blister formed into an open wound that resisted healing. The patient had been undergoing various types of treatment at a specialized wound center with no results. Vascular imaging of the patient's lower extremities revealed significant compromise to the arterial circulation of the left lower leg. The patient presented to our center with a mild limp and in pain.

On 10-29-04, after 30 minutes of exposure to clinical ETT, the patient reported a noticeable decrease in pain. After 1 week of daily clinical ETT, the patient noted an 80% reduction in pain. The patient also showed no evidence of a limp at this time. The patient reported that she was completely pain free by the end of week 2.

Her forensic photographs show a dramatic change with a significant amount of healing after the first week of exposure to clinical ETT. By the end of the second week, the wound was healed over and the color of the leg showed a significant improvement in circulation.



The forensic photographs shown above were taken as a baseline on 10-29-04. Note the size and depth of the open wound and how it has extended to include the surrounding tissue. The pale-gray color of the entire lower leg is evidence to the patient's vascular imaging that shows poor arterial circulation.



The top row of photographs was taken as a baseline on 10-29-04. Note the unhealed open wound and pale-gray color of the skin. The second row of photographs was taken after 1 week of daily exposure to clinical ETT. Note the significant level of healing and improvement in circulation (skin color) after only 1 week. The bottom row of photographs was taken on 11-10-04 after 2 weeks of daily clinical ETT. Note that the wound has healed over and that the patient's circulation has dramatically improved.



## Case Study #7 – 52-year-old female

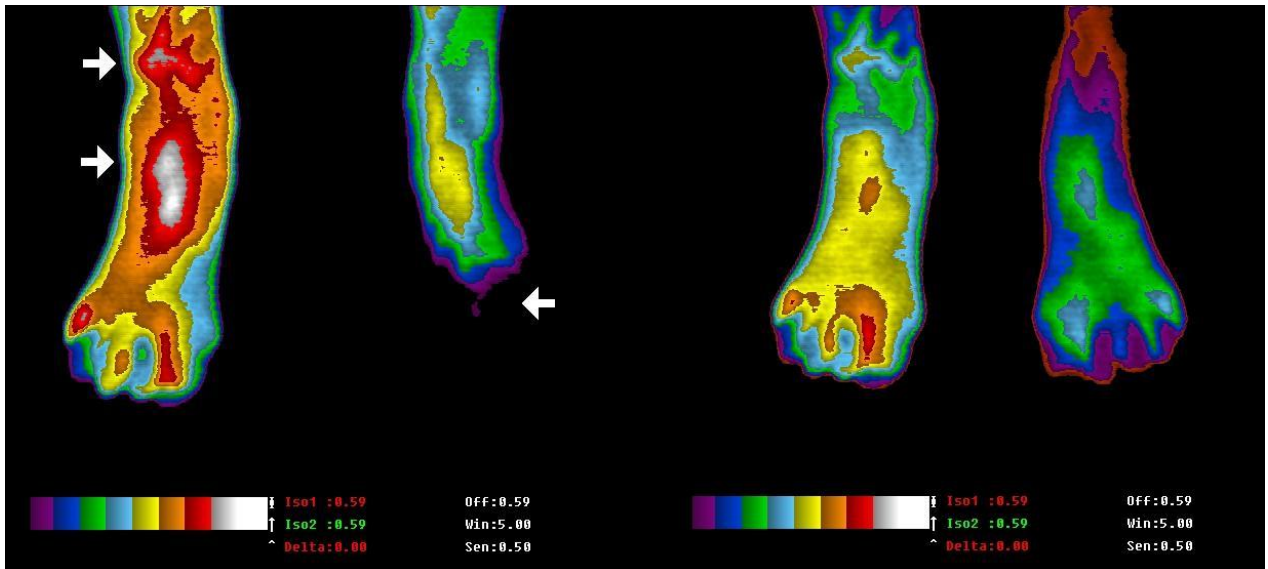
**The thermographic images below show a dramatic reduction in inflammation after only 30 minutes exposure to Electron Transfer Technology.**

The case presented below was taken from a randomized clinical controlled study. The subject was exposed to clinical Electron Transfer Technology (ETT) on 8-12-04 and observed for changes 30 minutes later and followed up with clinical treatment over a 1 week period. Progress was monitored with High-Resolution Medical Infrared Imaging and standardized clinical outcome assessment questionnaires (quadruple VAS).

The patient in this study presented on 8-12-04 as a 52-year-old female with significant acute right ankle and foot pain, swelling at the ankle and proximal foot, and walking with a pronounced limp. The patient noted that she had turned her ankle while carrying groceries three days previously. Her presentation was typical of an acute inversion sprain of the right ankle. The patient had been applying ice and taking over-the-counter anti-inflammatory medication with minimal relief.

On 8-12-04, after 30 minutes of exposure to clinical ETT, the patient reported an immediate 50% reduction in pain. She noted that she was “shocked” by the amount of instantaneous relief. After 3 days of clinical ETT, the patient noted a 90% reduction in pain. After 5 days of treatment, the patient reported that her pain was nearly gone and the swelling had completely resolved.

Her infrared images show a pronounced change with a significant improvement in inflammation in the right ankle and foot region. The images below clearly demonstrate the amount of reduction in inflammation after ETT use.



The images above are of the feet and ankles taken before and after 30 minutes exposure to clinical *earthing*. The arrows denote the most significant areas of inflammation in the right foot and ankle. The arrow in the left foot denotes a lack of circulation. Her toes are as cold as the room temperature and cannot be seen (thermal amputation). Note the considerable reduction in inflammation in the right image taken after 30 minutes of exposure to clinical ETT. You will also note the return of circulation in the left foot.

## Case Study #8 – 33-year-old female

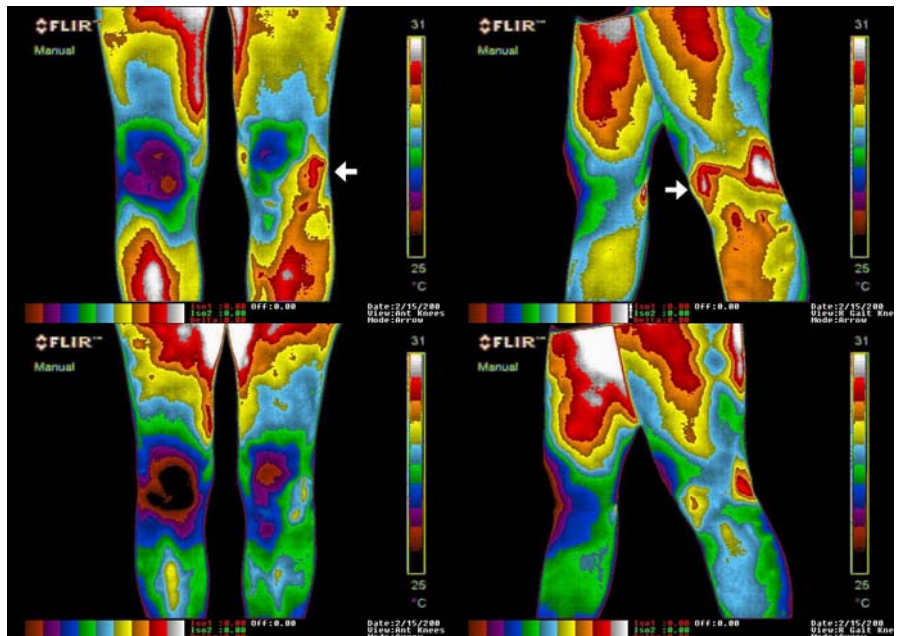
### ***The thermographic images below show a dramatic reduction in chronic inflammation after only 30 minutes exposure to Electron Transfer Technology***

The case presented below was taken from a randomized clinical controlled study. The subject was exposed to clinical Electron Transfer Technology (ETT) on 2-15-05 and observed for changes 30 minutes later and followed up with clinical visits over a 2 week period. Progress was monitored with High-Resolution Medical Infrared Imaging and standardized clinical outcome assessment questionnaires (quadruple visual analogue pain scales).

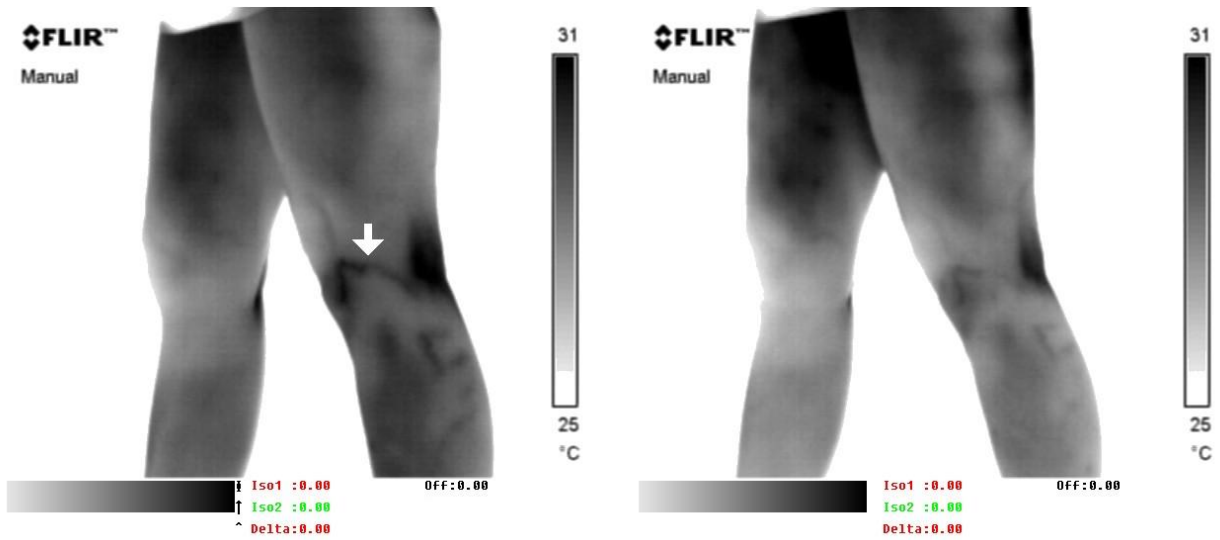
The patient in this study presented on 2-15-05 as a competitive long distance runner with chronic left knee pain over the past 6 months. The subject's condition began as a mild irritation noted at the end of her usual long distance training runs. The pain had progressed to the current level where it is noticeable with every step and is so severe that it stops her from running at the two mile point. The patient was notably concerned that she would no longer be able to enjoy her sport, much less ever compete again. She also advised that she had made plans months ago for an exotic two week hiking trip in another country and was scheduled to leave in two weeks. The subject was preparing to cancel her trip due to her current level of pain with hiking.

On 2-15-05, after her initial 30 minutes of exposure to clinical ETT, the patient reported a 30% reduction in pain. After 5 days of clinical ETT, the patient reported a 70% overall reduction in pain. Upon returning for treatment after the weekend, the patient reported that she had felt so good that she tried hiking a little to "test things out". She noted that the hike did not increase her pain and that she was able to keep up with her friends. Because of this level of improvement, the patient decided not to cancel her trip. At the end of 2 weeks of treatment the patient noted that her pain had completely resolved and that she felt great. Upon returning from her trip, the patient noted that she had no pain whatsoever during the entire time hiking through mountainous terrain. She slowly returned to her regular training levels and competed in long distance runs with no further problems.

The images on the right are of the knees taken before and after 30 minutes exposure to clinical *earthing*. The arrows in the upper two images denote the most significant areas of inflammation in the left knee. Note the considerable reduction in inflammation in the lower two images taken after 30 minutes of exposure to clinical ETT.

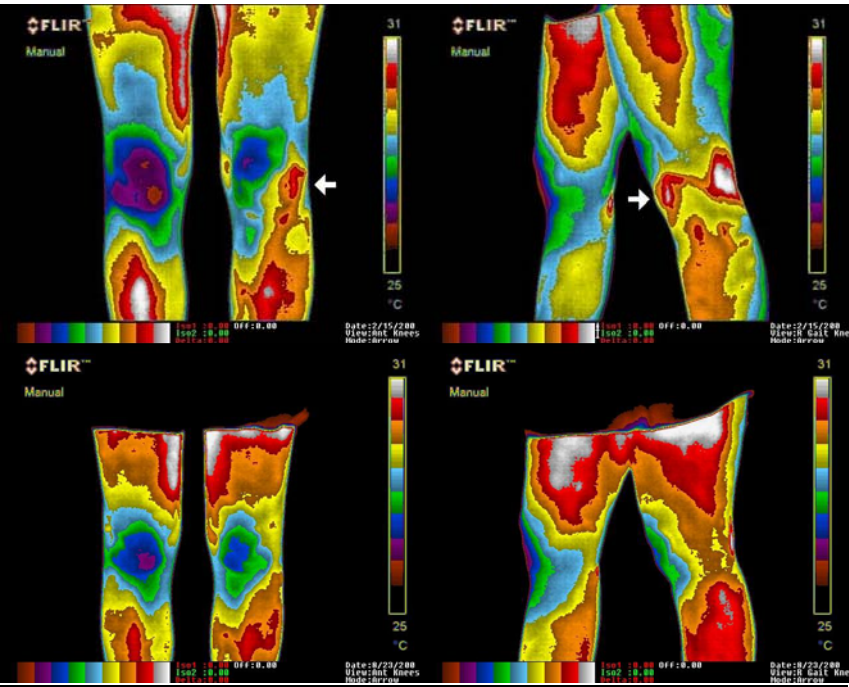


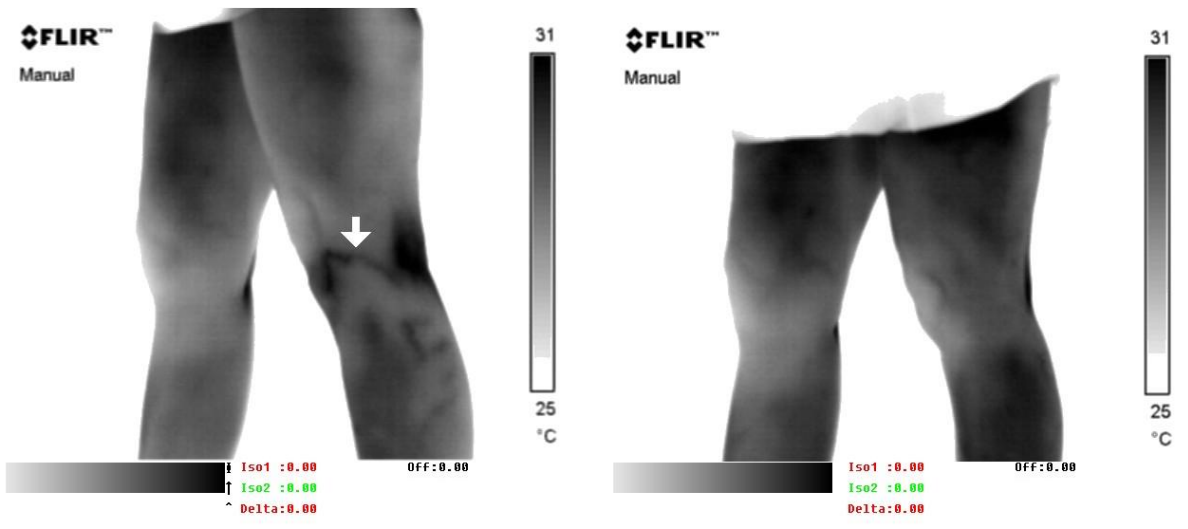




The images above are of the knees taken before and after 30 minutes exposure to clinical *earthing*. The images show the side of the left knee in a format that allows a clear view of blood vessels. The arrow denotes a large hot blood vessel bringing more blood into the area as part of the inflammatory process. The image to the left shows a considerable reduction in inflammation with the blood vessel almost completely gone after 30 minutes of exposure to clinical ETT.

**6 month follow-up:**  
 The arrows in the upper two images denote the initial areas of inflammation in the left knee. The lower two images were taken 6 months later after the patient had resumed her normal training and competitions. Note the return of thermal symmetry and lack of inflammation.





**6 month follow-up:** The arrow in the left image denotes the initial large hot blood vessel involved in the area of inflammation in the left knee. The image on the right was taken 6 months later after the patient had resumed her normal training and competitions. Note that the blood vessel is no longer present due to the resolution of the inflammation.

## Case Study #9 – 57-year-old male

**The thermographic images below show the dramatic reduction in inflammation that resulted in significant pain resolution after only 4 nights sleeping on the Electron Transfer Technology sleep system**

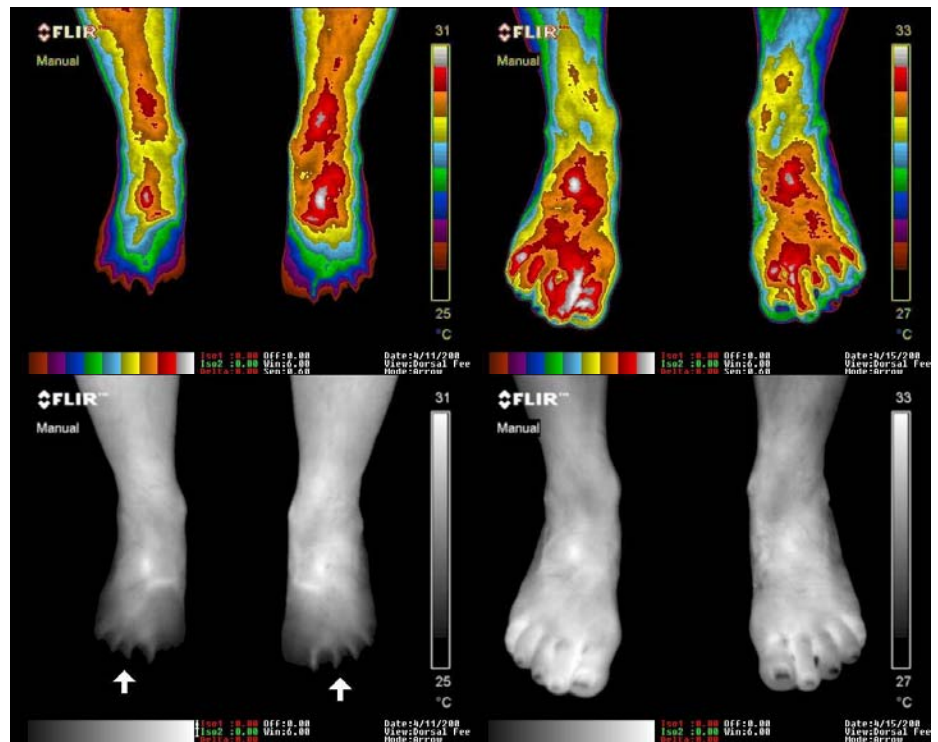
The case presented below was taken from a randomized clinical controlled study. The subject was provided with an Electron Transfer Technology sleep system (ETT) on 4-11-05 and observed for changes. Progress was monitored with High-Resolution Medical Infrared Imaging and standardized clinical outcome assessment questionnaires (quadruple visual analogue pain scales and sleep).

The patient in this study presented on 4-11-05 as a 57-year-old male with chronic bilateral foot and ankle pain for the past two years. The patient noted that the pain would occasionally be worse on one side or the other, but that more frequently it was the left side that was more painful.

On 4-13-05, after 2 nights of sleeping on the ETT system, the patient reported a 60% reduction in pain. After using the ETT sleep system for 4 nights, the patient reported that the pain in his feet and ankles had reduced by more than 80%. A follow-up report from the patient after using the ETT sleep system for 4 weeks noted complete resolution of his pain with only occasional stiffness.

His infrared images show a significant change with a pronounced improvement in circulation and reduction in inflammation. The images below demonstrate the significant changes from the baseline images taken on 4-11-05 (before ETT use) to the final images taken on 4-15-05 after 4 nights of sleeping on the ETT sleep system.

The images on the left are of the feet and ankles taken as a baseline on 4-11-05 (prior to ETT use). The arrows denote the decreased circulation in the feet. The significantly larger red areas in the left ankle and foot agree with the patient's account of more frequent pain on the left. The images on the right were taken on 4-15-05 after 4 nights of sleeping on the ETT sleep system. Note the complete return of normal circulation and reduction in inflammation.



## Case Study #10 – 67-year-old female

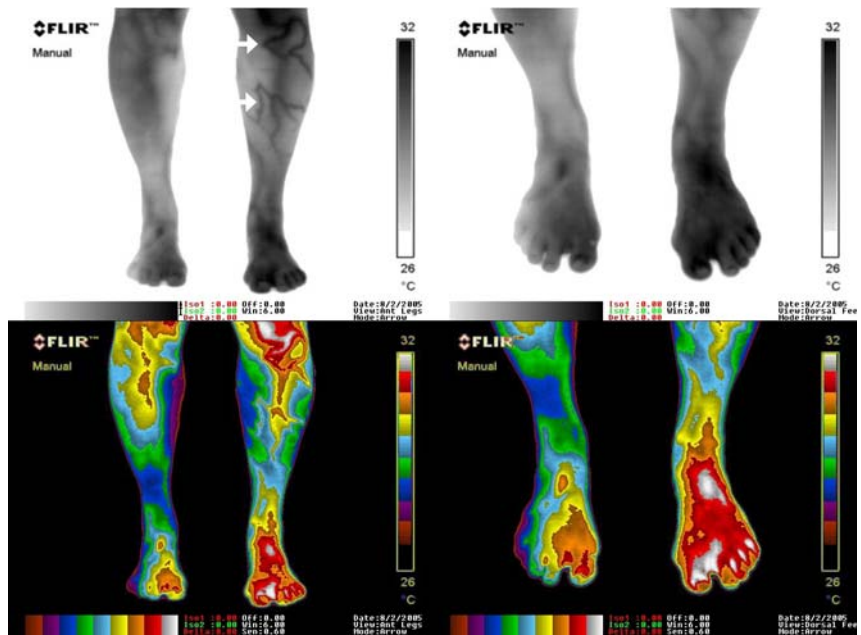
### ***The thermographic images below show a dramatic reduction in 5 years of chronic neurovascular pathology after only 30 minutes exposure to Electron Transfer Technology***

The case presented below was taken from a randomized clinical controlled study. The subject was exposed to clinical Electron Transfer Technology (ETT) on 8-2-05 and observed for changes 30 minutes later and followed up with clinical visits over a 12 week period. Progress was monitored with High-Resolution Medical Infrared Imaging and standardized clinical outcome assessment questionnaires (quadruple visual analogue pain scales).

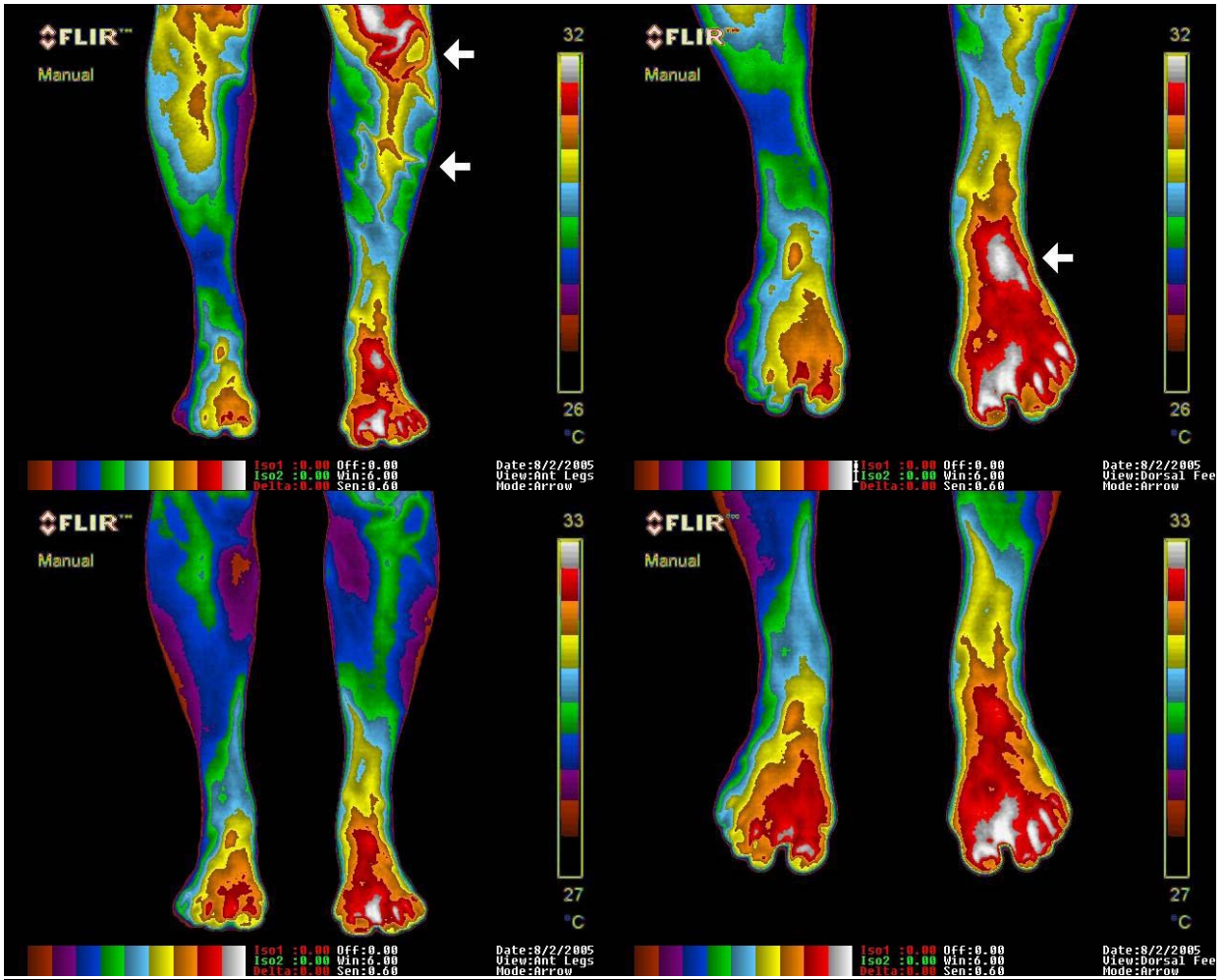
The patient in this study presented on 8-2-05 with a history of chronic sharp burning pain in both feet with a significant increase in symptoms on the left. The subject was diagnosed with erythromelalgia 5 years previously. She noted that aspirin and cold temperatures helped, while closed-toe shoes and hotter weather significantly increased her pain. The patient had been unable to wear anything but loose fitting open-toe beach-type shoes for the past 5 years. She also had to completely refrain from sun exposure to her legs and feet. Her condition prevented her from going on long walks or from exercising. This presentation is typical for patients with erythromelalgia. The cause of the condition is unknown, but involves a neurovascular pathology.

On 8-2-05, after 30 minutes of exposure to clinical ETT, the patient reported a 30% reduction in pain that lasted for 48 hours. After two weeks of clinical ETT, the patient reported a 50% reduction in pain that she felt was “remarkable.” Within 4 weeks of treatment, the patient noted that her pain had reduced by 70%. At this point the patient was given an ETT sleep system and her clinical treatments were stopped. The patient noted that her condition continued to improve over the next 4 weeks and that she had not needed to take any aspirin. She was now able to wear closed-toe shoes for the first time in years. Her pain levels had also reduced by 80% overall. By 12 weeks, her pain had improved more than 90% and she noted that she was now able to sit in the sun without any worry of increased symptoms.

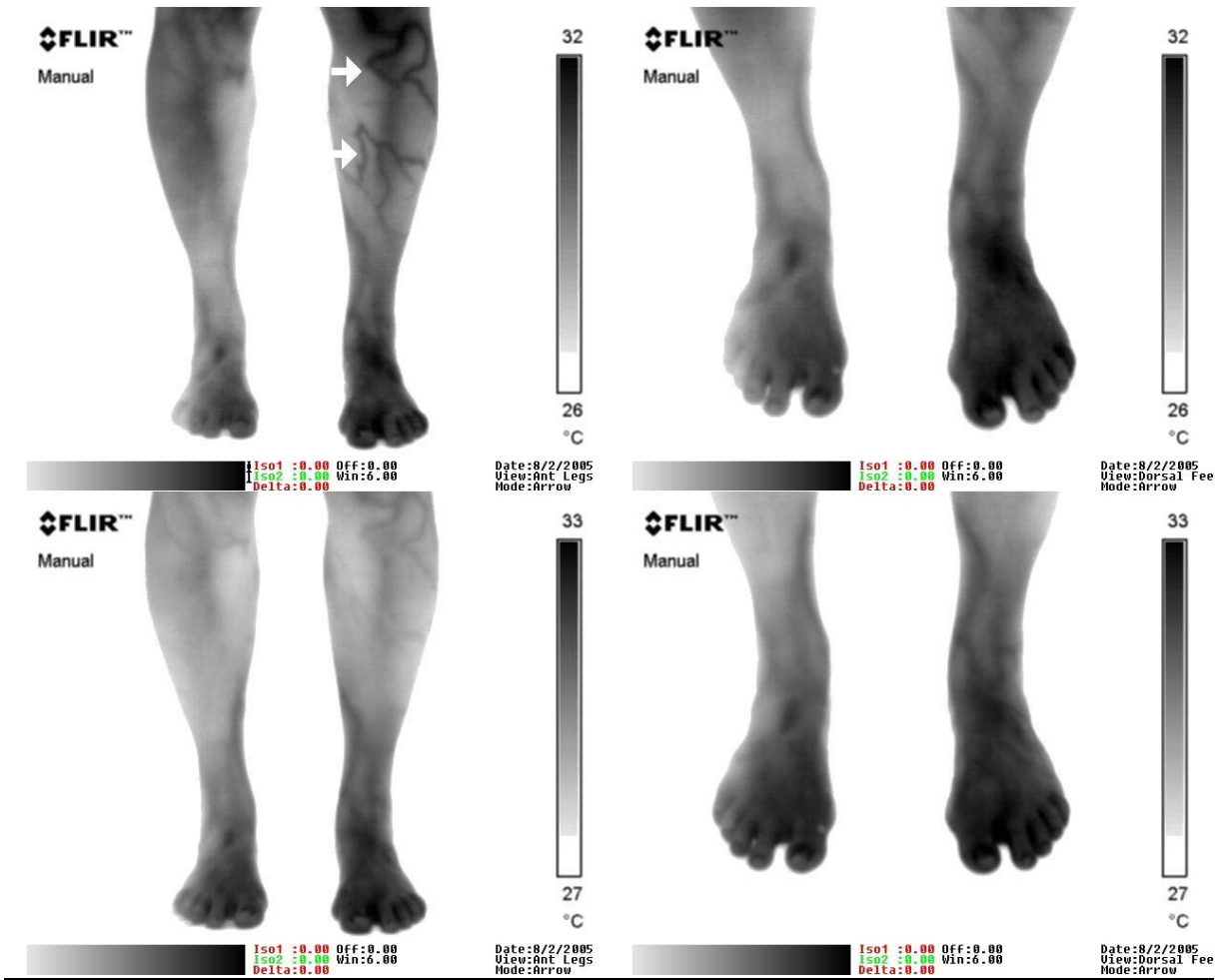
The images to the right are of the lower legs and feet prior to exposure to clinical *earthing*. The arrows indicate the areas of dilated and hot blood vessels. The significant redness (heat) over the entire left foot agrees with the patient’s complaint of increased symptoms on this side.







The images above are of the lower legs and feet before and after 30 minutes of exposure to clinical *earthing*. The arrows indicate the areas of dilated and hot blood vessels along with the significantly increased heat (redness) over the entire left foot. The top two images are the baseline set taken before exposure to clinical ETT. The bottom two images are taken after 30 minutes of exposure to clinical *earthing*. Note the significant decrease in blood vessel heat in the left leg. Also note the decrease in heat over the left foot and a return to a more normal thermal symmetry between both feet.



The images above are of the lower legs and feet before and after 30 minutes of exposure to clinical *earthing*. The arrows indicate the areas of dilated and hot blood vessels. The top two images are the baseline set taken before exposure to clinical ETT. The bottom two images are taken after 30 minutes of exposure to clinical *earthing*. Note the significant decrease in blood vessel size and number in the left leg.

## Case Study #11 – 46-year-old male

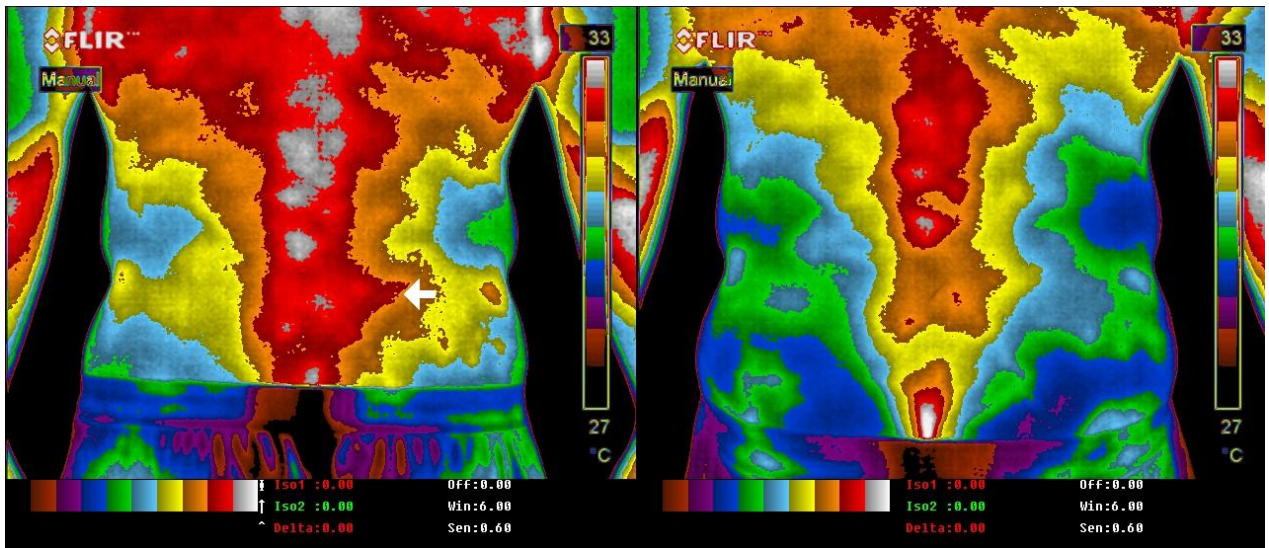
### ***The thermographic images below show a dramatic reduction in 10 years of chronic inflammation after only 30 minutes exposure to Electron Transfer Technology***

The case presented below was taken from a randomized clinical controlled study. The subject was exposed to clinical Electron Transfer Technology (ETT) on 4-20-05 and observed for changes 30 minutes later and followed up with clinical visits over a 4 week period. Progress was monitored with High-Resolution Medical Infrared Imaging and standardized clinical outcome assessment questionnaires (quadruple visual analogue pain scales).

The patient in this study presented on 4-20-05 as a 46-year-old male with a 10 year history of chronic low back pain with increased symptoms on the right. The patient noted daily pain with monthly flair-ups. He also noted that the pain frequently interfered with his sleep.

On 4-20-05, after an initial 30 minutes of clinical ETT, the patient reported an immediate reduction in pain of approximately 40%. By the end of the first week, the patient noted a 70% reduction in pain and more restful sleep. At week 4, the patient reported an overall 90% improvement in his back pain and no problems with sleep. Upon contacting the patient at 3 months post-treatment he noted that his back pain had resolved and that he only noticed occasional stiffness. The patient also noted that he hadn't had such restful sleep in years.

His infrared images show a significant change with a pronounced improvement in inflammation in the entire low back region. The images below demonstrate the significant changes before and after 30 minutes of exposure to clinical ETT.



The image on the left is of the low back taken as a baseline on 4-20-05 (prior to clinical ETT use). The arrow denotes the most significant area of inflammation, which also corresponds precisely with the subject's primary area of complaint. The image on the right was taken after 30 minutes of exposure to clinical *earthing*. Note the significant reduction in inflammation with a return of a more normal thermal symmetry.

## Case Study #12 – 44-year-old female

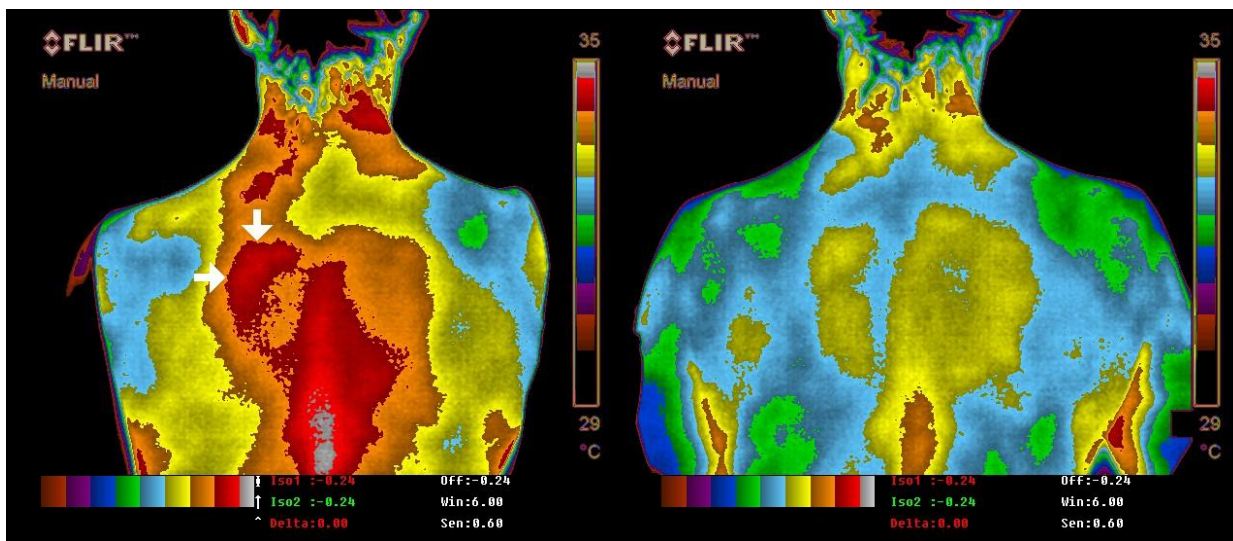
***The thermographic images below show the dramatic reduction in inflammation that resulted in significant pain resolution after only 4 nights sleeping on the Electron Transfer Technology sleep system***

The case presented below was taken from a randomized clinical controlled study. The subject was provided with an Electron Transfer Technology sleep system (ETT) on 4-18-05 and observed for changes over an 8 week period. Progress was monitored with High-Resolution Medical Infrared Imaging and standardized clinical outcome assessment questionnaires (quadruple visual analogue pain scales and sleep).

The patient in this study presented on 4-18-05 as a 44-year-old female with significant chronic left mid back pain over a 9 month period. She also noted that her pain was causing interruptions in her sleep and that she always awakened with increased pain and stiffness. The patient had tried physical therapy and acupuncture treatments with poor results.

On 4-22-05, after 4 nights of sleeping on the ETT system, the patient reported a 30% reduction in pain, a 70% reduction in pain interfering with sleep, and a 30% reduction in waking stiff and sore. After using the ETT sleep system for 4 weeks, the patient reported an 80% reduction in pain, no interference with sleep, and a 70% reduction in waking stiff and sore. By 8 weeks the patient noted that her pain had resolved, she was sleeping the best she had in years, and that she awakened with only minor left mid back stiffness.

Her infrared images show a significant change with a pronounced improvement in inflammation in the left mid back region. The images below demonstrate the significant changes from the baseline images taken on 4-18-05 (before ETT use) to the final images taken on 4-22-05 after 4 nights of sleeping on the ETT sleep system.



The image on the left is of the mid back and shoulders taken as a baseline on 4-18-05 (prior to ETT use). The arrows denote the most significant area of inflammation, which also correspond precisely with the subject's areas of complaint. The image on the right was taken on 4-22-05 after 4 nights of sleeping on the ETT sleep system. Note the complete resolution in inflammation with a return of normal thermal symmetry.



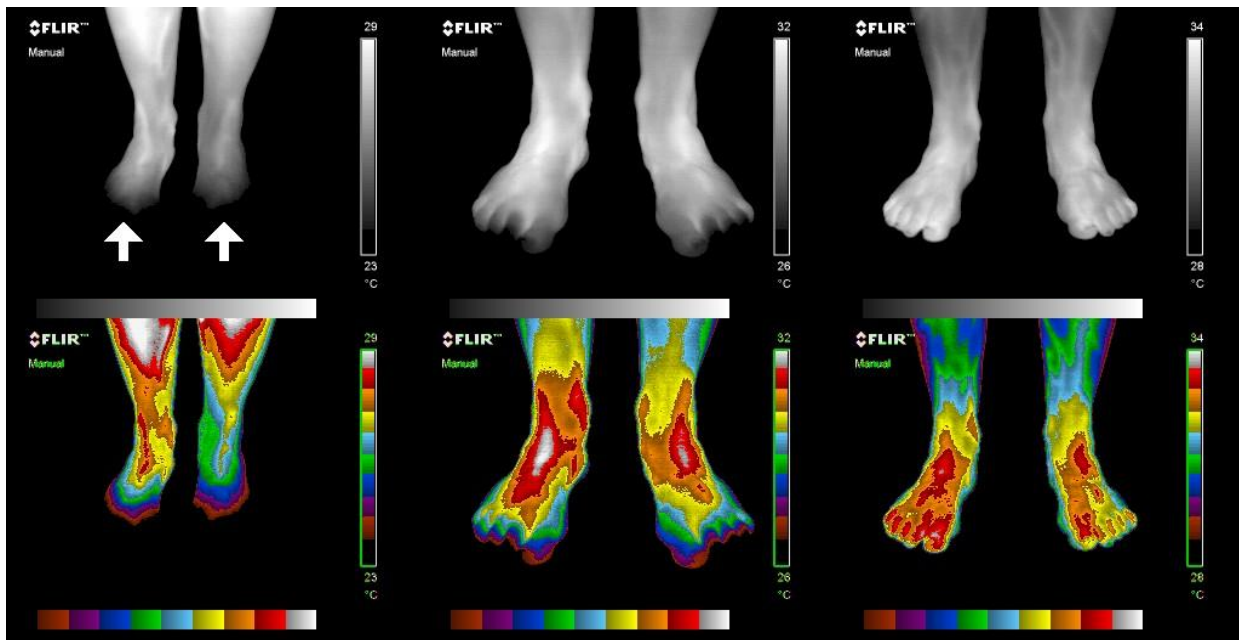
## Case Study #13 – 52-year-old female

**The thermographic images below show a dramatic improvement in circulation after only 2 weeks sleeping on the Electron Transfer Technology sleep system**

The case presented below was taken from a randomized clinical controlled study. The subject was provided with an Electron Transfer Technology sleep system (ETT) on 12-6-04 and observed for changes over a 4 week period. Progress was monitored with High-Resolution Medical Infrared Imaging and standardized clinical outcome assessment questionnaires (quadruple visual analogue pain scales and sleep).

The patient in this study presented on 12-6-04 as a 52-year-old female with long history of cold feet. She noted that as long as she could remember she had very cold feet. The problem was most notable in the past 20 years. In winter, the patient had to wear thick woolen socks to bed. She also reported that on most days in summer she still had to wear a light pair of socks while she slept. At times in the winter her feet would get so cold they hurt. Her doctor noted that he could find nothing wrong.

On 12-20-04, after 2 weeks of sleeping on the ETT system, the patient reported that she was “shocked” by the changes in her feet. She said that they felt “hot” to her. She noted that she had to feel her feet with her hands on occasion to prove to herself that they felt this good. The patient reported that she noticed an improvement by the end of the first week, but that by the end of the second week her feet were significantly better. By the 4<sup>th</sup> week the patient noted that she no longer needed any socks in bed. This was especially significant because it was winter. The patient reported that for the first time in all her memory her feet felt normal.



The images above show a timeline of the feet from baseline on the far left (prior to ETT use) to 2 weeks post sleep system use on the far right. You will note by the arrows in the baseline images that the toes and distal feet are so cold that they are the same temperature as the room (thermal amputation). The center and far right images show a dramatic return of normal circulation after using the ETT sleep system for 2 weeks.

## Case Study #14 – 59-year-old female

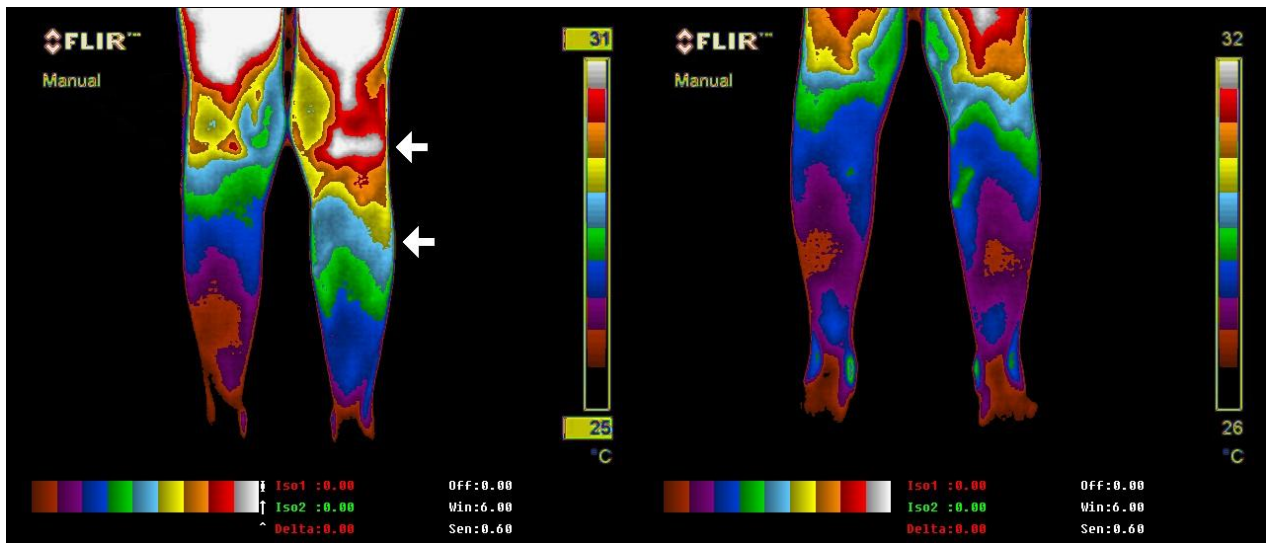
### **The thermographic images below show a dramatic reduction in 2 years of chronic inflammation after exposure to Electron Transfer Technology**

The case presented below was taken from a randomized clinical controlled study. The subject was exposed to clinical Electron Transfer Technology (ETT) on 1-10-05 and observed for changes with clinical visits over a 12 week period. Progress was monitored with High-Resolution Medical Infrared Imaging and standardized clinical outcome assessment questionnaires (quadruple visual analogue pain scales).

The patient in this study presented on 1-10-05 as a 59-year-old female with chronic right posterior knee and leg pain over the past 2 years. The subject's condition began as a result of a fall while walking down stairs. The patient has had orthopedic examinations and MRI without any findings of damage to the knee. The only thing that has helped with the pain is anti-inflammatory medications. The patient presented with a mild right sided limp.

On 1-10-05, the patient began daily exposure to clinical ETT. After the third day of treatment, the patient noted that her pain was reduced by approximately 30%. By the end of the week, the patient reported a 50% reduction in pain. The patient continued with treatment and reported a gradual, but significant continued improvement in her condition. Her treatment frequency was also gradually reduced. After 4 weeks, she noted a 70% reduction in pain. Her limp was also noticeably improved by this time. By 8 weeks, she reported an 80% improvement in pain. At the end of 12 weeks, the patient reported complete resolution of her pain and limp with only occasional stiffness.

Her infrared images show a significant change with a pronounced improvement in inflammation in the right posterior knee and leg.



The above images are of the posterior knees and legs taken before and after clinical exposure to *earthing*. The arrows denote the most significant areas of inflammation in the baseline images taken on 1-10-05 (prior to ETT use). Note the significant reduction in inflammation in the right image taken after 4 weeks of clinical ETT. The image shows a return of normal thermal symmetry with significant reduction in inflammation.

## Case Study #15 – 36-year-old male

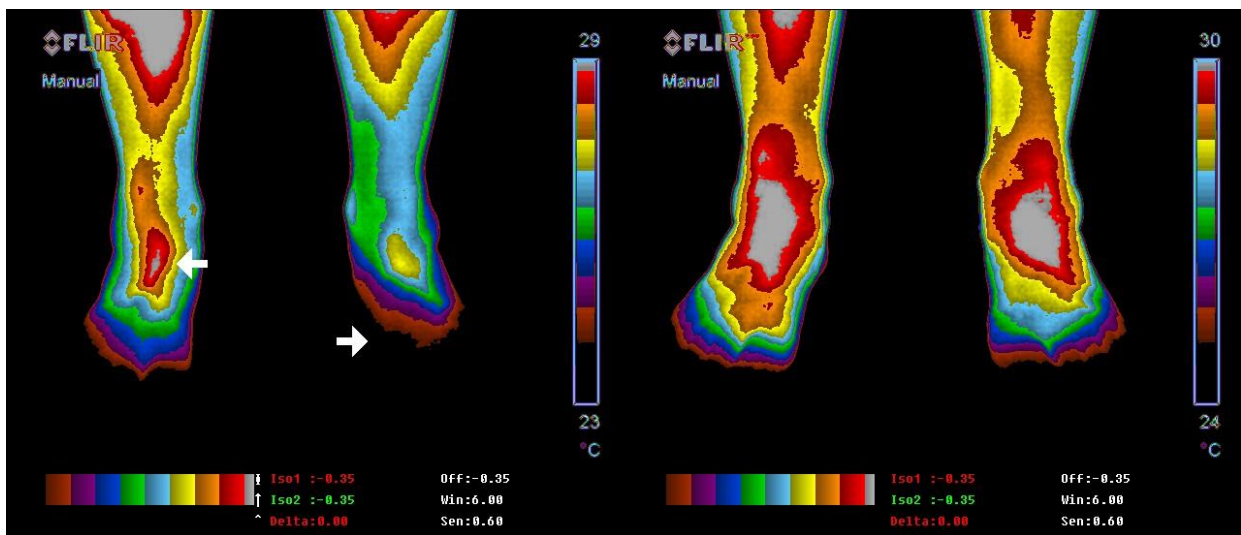
### ***The thermographic images below show a dramatic reduction in chronic inflammation after only one week of exposure to Electron Transfer Technology***

The case presented below was taken from a randomized clinical controlled study. The subject was exposed to clinical Electron Transfer Technology (ETT) on 2-7-05 and observed for changes with clinical visits over an 8 week period. Progress was monitored with High-Resolution Medical Infrared Imaging and standardized clinical outcome assessment questionnaires (quadruple visual analogue pain scales).

The patient presented on 2-7-05 as a 36-year-old male with chronic right foot pain over the past 4 months. The subject's condition began a few hours after playing softball. There was no single traumatic event of onset. The patient had had a medical examination with a diagnosis of inflammation secondary to a sprain. The patient had been taking over-the-counter anti-inflammatory medications with limited results.

On 2-9-05, after 2 days of clinical ETT, the patient reported a 30% reduction in pain. By the end of the week, the patient noted that he was very surprised with the level of pain reduction. He noted that the pain was down over 50%. The patient continued with treatment with a gradual decrease in pain to the point of complete resolution after 4 weeks of care. By the 8<sup>th</sup> week the patient was back playing softball.

His infrared images show a significant change with a pronounced improvement and return to normal thermal symmetry.



The above images are of the feet taken before and after clinical exposure to *earthing*. The image on the left is the baseline image taken on 2-7-05 prior to ETT use. The arrows in the image denote the area of inflammation in the right foot and a decrease in circulation in the left. The right image was taken after only one week of exposure to clinical ETT. Note the significant improvement in the image with a return of normal thermal symmetry.

## Case Study #16 – 42-year-old female

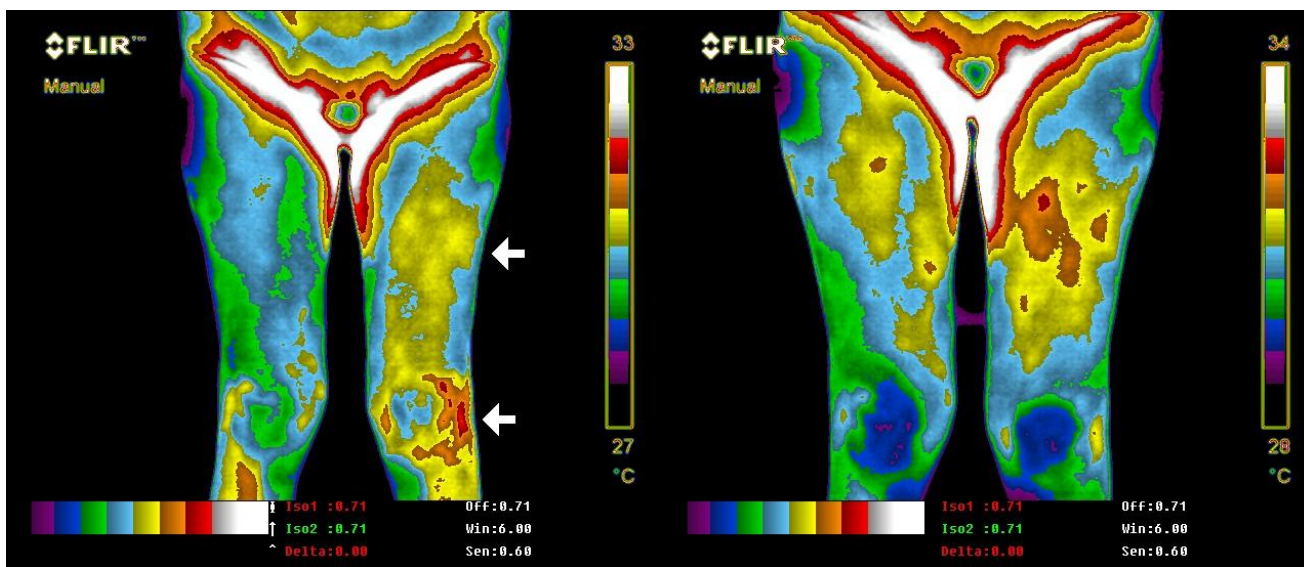
### ***Thermographic images below show reduction in chronic inflammation that resulted in significant pain resolution after 6 weeks exposure to Electron Transfer Technology***

The case presented below was taken from a randomized clinical controlled study. The subject was provided with an Electron Transfer Technology sleep system (ETT) on 5-9-05 and observed for changes with follow up clinical visits over a 6 week period. Progress was monitored with High-Resolution Medical Infrared Imaging and standardized clinical outcome assessment questionnaires (quadruple visual analogue pain scales).

The patient in this study presented on 5-9-05 with chronic left knee and thigh pain over the past 2 years. The subject noted that her pain had been gradually increasing over this time to the point where stair use was becoming difficult. She was unsure how the problem began, but she noted a history of traumatic falls while waterskiing. At this time the patient had been refraining from waterskiing for over a year due to the pain.

On 5-16-05, after sleeping on the ETT system for one week, the patient reported a 50% reduction in pain. After two weeks, the patient noted that her pain had reduced by 60% and that stair use was becoming easier. After four weeks of sleeping on the ETT system, the patient reported an overall 80% reduction in pain. By six weeks, the subject noted that her pain was nearly resolved and that using the stairs no longer increased her pain. A follow up contact with the patient after three months noted that her pain had resolved and that she was back waterskiing with not problems.

Her infrared images show a significant change with pronounced improvement in inflammation in the left knee and thigh.



The above images are of the anterior thighs and knees taken before and after use of the ETT sleep system. The image on the left is the baseline image taken on 5-9-05 prior to ETT use. The arrows in the image denote the primary areas of inflammation in the left knee and thigh. The image on the right was taken after 4 weeks of using the ETT sleep system. Note the dramatic reduction in inflammation and a return of normal thermal symmetry.



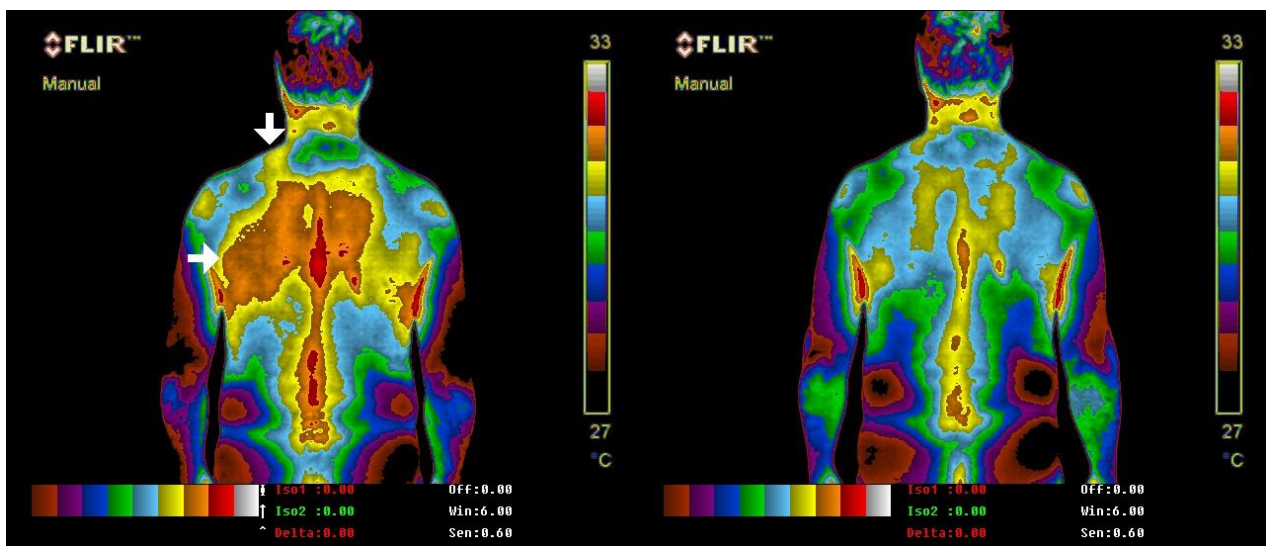
## Case Study #17 – 54-year-old male

### ***The thermographic images below show the dramatic reduction in inflammation that resulted in significant pain resolution after only 4 nights sleeping on the Electron Transfer Technology sleep system***

The case presented below was taken from a randomized clinical controlled study. The subject was provided with an Electron Transfer Technology sleep system (ETT) on 4-4-05 and observed for changes over an 8 week period. Progress was monitored with High-Resolution Medical Infrared Imaging and standardized clinical outcome assessment questionnaires (quadruple visual analogue pain scales and sleep).

The patient in this study presented on 4-4-05 as a 54-year-old left handed male with significant chronic left mid back and neck pain over the past year. The subject noted that his pain began after a long day of hammer use while on the job as a carpenter. He presented with a diagnosis of chronic muscular strain and connective tissue inflammation. The patient had been using prescribed anti-inflammatory medications which helped control the pain. He also tried a few weeks of physical therapy with limited results. He noted that he was currently living with the pain and working around it as best he could while on the job. The patient also reported that the pain interfered with his sleep and that he woke with increased pain and stiffness in the left mid back and neck.

On 4-11-05, after 4 nights of sleeping on the ETT system, the patient reported a 30% reduction in pain, a 50% reduction in pain interfering with sleep, and a 30% reduction in waking stiff and sore. After using the ETT sleep system for 4 weeks, the patient reported a 70% reduction in pain, a 70% reduction in pain interfering with sleep, and a 60% reduction in waking stiff and sore. By 8 weeks the patient noted that his pain had resolved, he was sleeping without pain, and that he awakened with only occasional neck and mid back stiffness. He also reported no increased pain or problems with work.



The image on the left is of the entire back taken as a baseline on 4-4-05 (prior to ETT use). The arrows denote the most significant area of inflammation, which also correspond precisely with the subject's areas of complaint. The image on the right was taken on 4-11-05 after 4 nights of sleeping on the ETT sleep system. Note the complete resolution in inflammation with a return of normal thermal symmetry.

## Case Study #18 – 39-year-old female

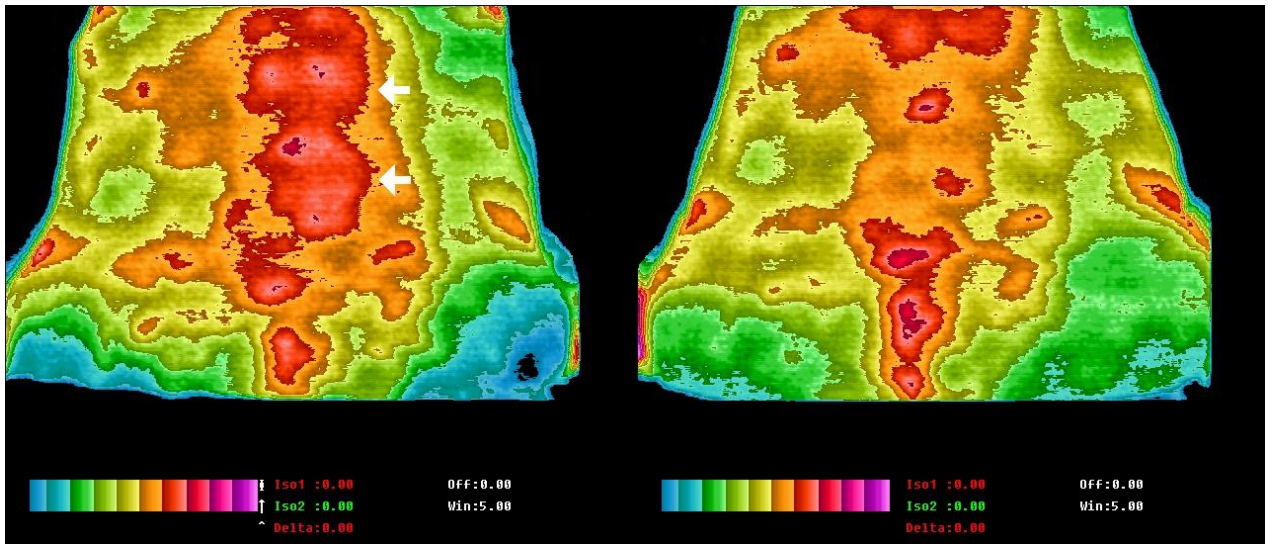
**The thermographic images below show a dramatic reduction in acute inflammation after only 30 minutes exposure to Electron Transfer Technology**

The case presented below was taken from a randomized clinical controlled study. The subject was exposed to clinical Electron Transfer Technology (ETT) on 9-22-04 and observed for changes 30 minutes later and followed up with clinical visits over a 2 week period. Progress was monitored with High-Resolution Medical Infrared Imaging and standardized clinical outcome assessment questionnaires (quadruple visual analogue pain scales).

The patient in this study presented on 9-22-04 as a 39-year-old female with significant acute low back pain with an increase in symptoms on the right. She presented in acute distress and crying out with any use of her back. She was unable to walk on her own or straighten up at the waist. The patient noted that she had awakened with low back stiffness and that when she had bent down to tie her shoes she crumpled to the floor in pain. She had been helping a friend move furniture and boxes the day before. Any movement whatsoever caused excruciating pain in her low back.

On 9-22-04, after 30 minutes of exposure to clinical ETT, the patient reported an immediate 70% reduction in pain. She noted that she couldn't believe it. She stood on her own and was able to walk out of the office. After 3 days of clinical ETT, the patient reported a 90% reduction in pain. Within 2 weeks, her pain was completely resolved.

Her infrared images show a significant change with a pronounced improvement in inflammation in the low back region after only 30 minutes of exposure to clinical ETT.



The image on the left is of the low back taken as a baseline on 9-22-04 (prior to ETT use). The arrows denote the most significant areas of inflammation, which also correspond precisely with the subject's areas of complaint. The image on the right was taken after 30 minutes of exposure to clinical ETT. Note the significant reduction in acute inflammation.

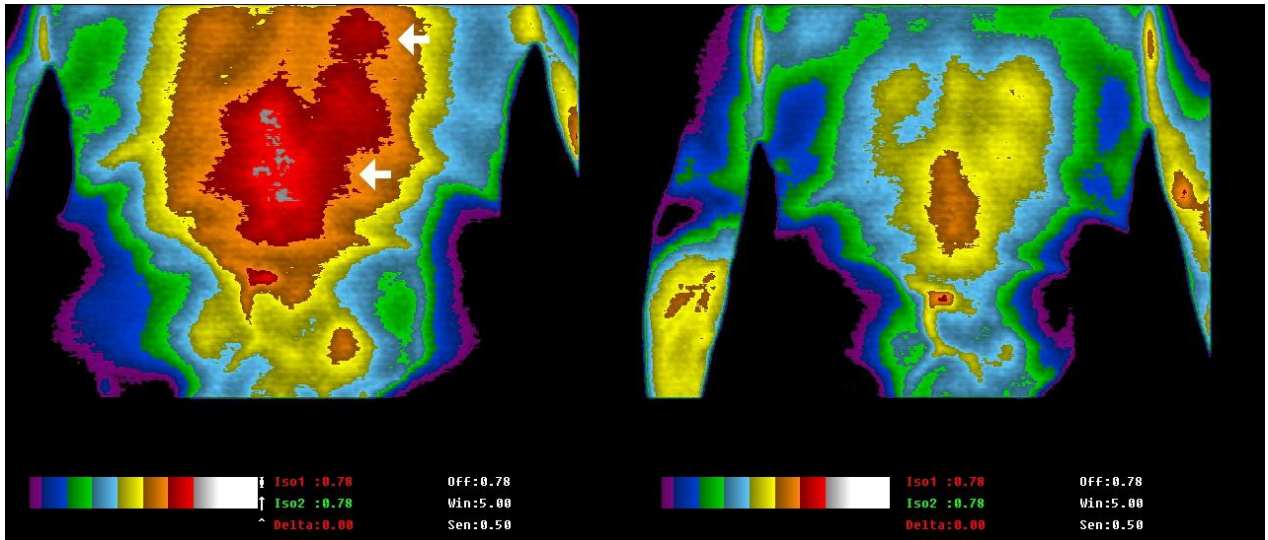
## **Case Study #19 – 66-year-old male**

### ***The thermographic images below show a dramatic reduction in 4 years of chronic inflammation after only 4 nights sleeping on an Electron Transfer Technology sleep system***

The case presented below was taken from a randomized clinical controlled study. The subject was provided with an Electron Transfer Technology sleep system (ETT) on 10-11-04 and observed for changes with occasional follow up clinical visits over a 12 week period. Progress was monitored with High-Resolution Medical Infrared Imaging and standardized clinical outcome assessment questionnaires (quadruple visual analogue pain scales and sleep).

The patient in this study presented on 10-11-04 as a 66-year-old male with chronic low back and right mid back pain for the past 4 years. He has a history of multiple injuries to the same areas resulting from college football. His condition had also caused him to lose sleep and awaken with increased stiffness and pain. The patient advised that the pain had caused him to give up golf, which he enjoyed playing 2-3 times a week.

On 10-15-04, after 4 nights of sleeping on the ETT system, the patient reported a 40% overall reduction in pain, a 65% reduction in pain interfering with sleep, and a 30% reduction in waking stiff and sore. After using the ETT sleep system for 4 weeks, the patient reported that his pain had reduced by 75% with an 80% reduction in pain interfering in sleep and a 60% reduction in waking stiff and sore. Over the next 4 weeks the subject continued to improve with use of the ETT sleep system. By 8 weeks, the patient felt good enough to try golfing again. He reported that his symptoms were not affected by playing golf. At 10 weeks, the patient noted that he was completely free of pain, sleeping great, and awakening with no pain or stiffness. The subject was elated that he was able to return to playing golf.



The image on the left is of the mid and lower back taken as a baseline on 10-11-04 (prior to ETT use). The arrows denote the most significant areas of inflammation, which also correspond precisely with the subject's areas of complaint. The image on the right was taken on 10-15-04 after 4 nights of sleeping on the ETT sleep system. Note the significant improvement in inflammation with greater thermal symmetry.



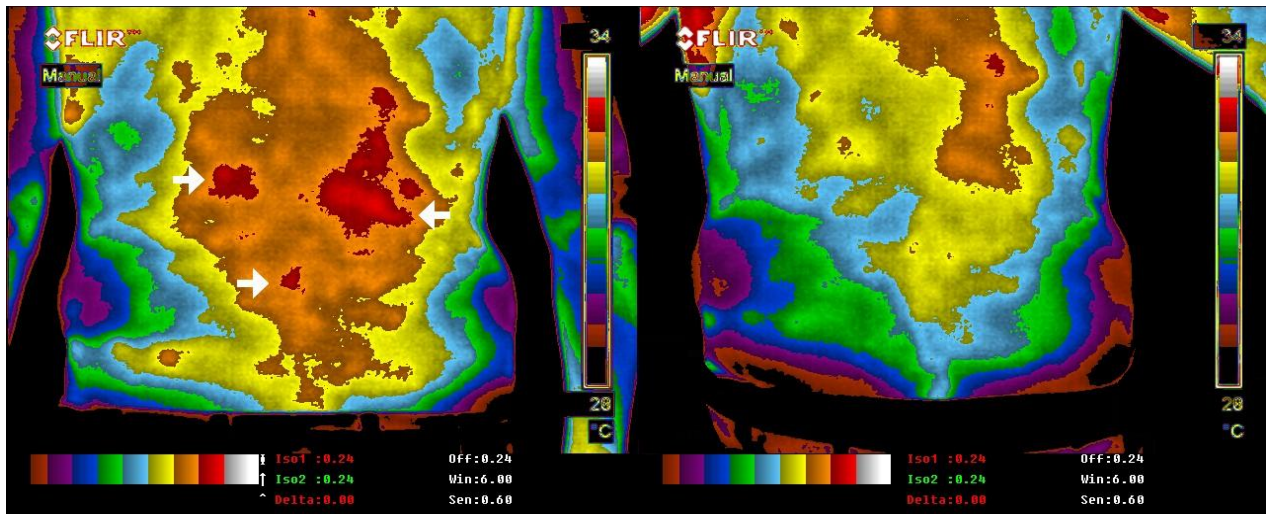
## Case Study #20 – 53-year-old male

### ***The thermographic images below show a dramatic reduction in 10 years of chronic inflammation after only 4 nights sleeping on an Electron Transfer Technology sleep system***

The case presented below was taken from a randomized clinical controlled study. The subject was provided with an Electron Transfer Technology sleep system (ETT) on 7-11-05 and observed for changes with occasional follow up clinical visits over a 12 week period. Progress was monitored with High-Resolution Medical Infrared Imaging and standardized clinical outcome assessment questionnaires (quadruple visual analogue pain scales and sleep).

The patient in this study presented on 7-11-05 as a 53-year-old male with a 10 year history of chronic low back pain. His condition began as the result of an automobile accident. The patient advised that he received medical treatment including physical therapy immediately after the accident. His pain was significantly reduced, but returned on occasion with an increase in frequency over the years. He also reported that he always awakened with increased stiffness and pain. The subject noted that he had tried massage, physical therapy, and acupuncture with little to no change in his condition. He felt that these treatments gave him temporary results at best.

On 7-15-05, after 4 nights of sleeping on the ETT system, the patient reported a 35% overall reduction in pain. He noted that he was skeptical since other therapies gave similar results. After using the ETT sleep system for 4 weeks, the patient reported that his pain had reduced by 60%. The patient noted that this was the greatest amount of improvement that he could ever remember having. By 8 weeks, he reported that his symptoms had continued to improve and that his pain levels had reduced by 80%. At 12 weeks, the patient noted that his overall pain levels were down by 90% and that he was awakening with only mild pain and stiffness. A follow up call 2 months later noted that the patient's pain levels were down by 95% and he was increasing his activity levels with no increase in symptoms.



The image on the left is of the lower back taken as a baseline on 7-11-05 (prior to ETT use). The arrows denote the most significant areas of inflammation. The image on the right was taken on 7-15-05 after 4 nights of sleeping on the ETT sleep system. Note the significant improvement in inflammation in the entire low back region.